



PATIENT

Coco Foley

SPECIES

Canine

BREED

Chihuahua

SEX

Male Neutered

AGE

12 years

WEIGHT

10.9lbs

INTERPRETED BY

Maggie Machen
Lamy, DVM
DACVIM (Cardiology)

IMAGING PERFORMED BY

Pamela Harrigan,
RDCS

HOSPITAL NAME

VCA Palmer

REFERRING VET

Dr. Boudreau

INVOICE

29709

DATE

3/20/23

PRESENTING CLINICAL SIGNS

History: Progressive heart murmur, now grade IV/VI. History of cough since 2016 - had been stable with occasional use of hydrocodone, but became much worse in January 2023. BP: 180-190mmHg. Rads: tracheal collapse, generalized cardiomegaly, some pulmonary venous distension, no pulmonary edema. Hydrocodone 1mg q8h.

ECHOCARDIOGRAM FINDINGS

2D, m-mode, color flow and Doppler imaging is available.

Left ventricle: The LV diameter is mildly increased with hyperdynamic function. LV wall thicknesses are normal.

Left atrium: The left atrium is moderately dilated.

Mitral valve: The mitral valve is diffusely thickened with mild prolapse into the left atrial lumen. Moderate to severe eccentric mitral regurgitation with a normal velocity.

Aortic valve/Aorta: The aortic valve is normal in morphology and mobility. Normal aortic outflow velocity; laminar flow. No aortic insufficiency.

Right ventricle: Normal right ventricular diameter and morphology indicating no overt evidence of pulmonary arterial hypertension.

Right atrium: Normal RA dimension.

Tricuspid valve: The tricuspid valve appears mildly thickened with trace tricuspid regurgitation. Normal velocity.

Pulmonic valve/Pulmonary artery: The pulmonic valve is normal in morphology and mobility. No pulmonic insufficiency. Normal RVOT velocity; laminar flow.

Pericardium/other: No pericardial or pleural effusion noted. No obvious cardiac masses.

Heart rhythm: ECG reveals a sinus rhythm with an average HR of 170bpm.

2-Dimensional Measurements

Ao diam (cm)	1.2
LA diam (cm)	2.3
LA:Ao (Swe)	1.9
IVS thickness (cm)	0.5
LVID diastole (cm)	3.1
PW thickness (cm)	0.5
LVID systole (cm)	1.4
FS (%)	54

Doppler Measurements

PV Vmax (m/s)	0.7
AoV Vmax (m/s)	1.1
MR Vmax (m/s)	6.0
TR Vmax (m/s)	2.6
TR PG (mmHg)	27

INTERPRETATION OF THE FINDINGS

Chronic degenerative valve disease causing moderate to severe mitral and trace tricuspid regurgitation. Moderate left atrial enlargement indicates there is relatively low risk for imminent complication, however risk for progression to spontaneous congestive heart failure in the future is elevated. No additional issues are identified.

Given LA dilation, Pimobendan is recommended as below. Additionally, an ACE-I should be considered based upon mildly elevated blood pressure. Assessment of progression in the future will help predict long term outcome, however prognosis is guarded at this stage (B2).

The cough is suspected to be due to a combination of mainstem bronchi compression and potentially airway disease in this predisposed breed. A chronic symptom likely suggests



PATIENT
 Coco Foley

significant respiratory disease as the majority of the issue. Screening CXR, more aggressive hydrocodone, etc. may be useful.

SPECIES
 Canine

RECOMMENDATIONS

- Institute heart muscle support Pimobendan 0.3mg/kg PO q12h.
- Institute ACE-I 0.5mg/kg PO q12h.
- Consider more aggressive cough workup/treatment as discussed.
- Omega fatty acid supplementation and mild salt restriction may be of some long-term benefit.
- Once on Pimobendan for 3-5 days, anesthetic risk is considered mild if needed. Cardiac protective drug choices (opioid/benzodiazepine premedication, propofol or alfaxalone induction, isoflurane gas) are recommended. Pre-oxygenate for 5-10 minutes prior to induction. Monitor for arrhythmias, hypotension, and hypoxia both intra and post-operatively and intervene as necessary. Mild IV fluid restriction is recommended to avoid fluid overload. Avoid heart rate stimulating drugs such as atropine unless clinically indicated.
- Monitor for development of a cough, labored breathing, exercise intolerance or collapse episodes.

BREED
 Chihuahua

SEX
 Male Neutered

AGE
 12 years

WEIGHT
 10.9lbs

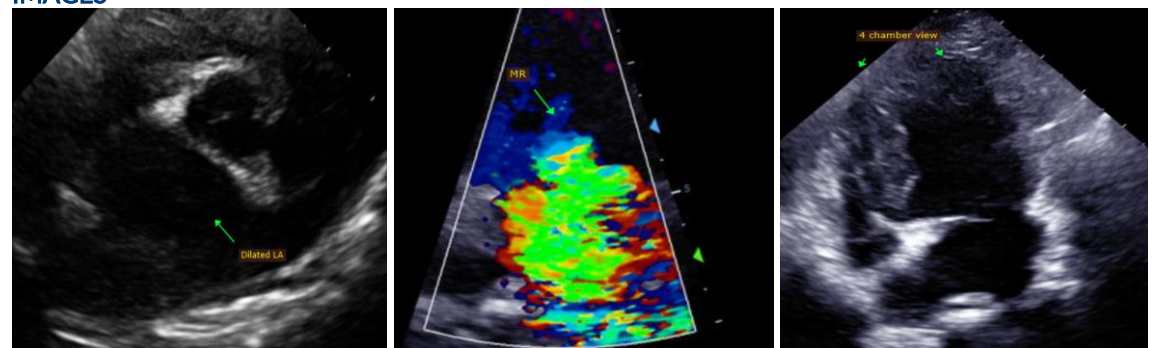
PLAN

- Recommend conservative monitoring with a recheck echocardiogram in 6 months, sooner if any development of clinical signs.

INTERPRETED BY

Maggie Machen
 Lamy, DVM
 DACVIM (Cardiology)

IMAGES



IMAGING PERFORMED BY

Pamela Harrigan,
 RDCS

HOSPITAL NAME

VCA Palmer

The information and recommendations provided are based on the images presented by the referring veterinarian. No evaluation can be communicated regarding pathology that was not visible in the image/video clips provided.

REFERRING VET

Dr. Boudreau

Thank you for this referral. This report was generated using transcription software, and minor dictation errors may be present. If the clinical or image interpretation does not parallel your findings or if I can be of any further assistance, please contact me.

INVOICE

29709

Maggie Machen Lamy, DVM
 Diplomate of the American College of Veterinary Internal Medicine (Cardiology)
 info@sonopath.com

DATE

3/20/23

Echocardiogram performed by: Pamela Harrigan, RDCS



PATIENT

Coco Foley

Pet Animal Ultrasound Service (4paus.com)

SPECIES

Canine

BREED

Chihuahua

SEX

Male Neutered

AGE

12 years

WEIGHT

10.9lbs

INTERPRETED BY

Maggie Machen
Lamy, DVM
DACVIM (Cardiology)

**IMAGING
PERFORMED BY**

Pamela Harrigan,
RDCS

HOSPITAL NAME

VCA Palmer

REFERRING VET

Dr. Boudreau

INVOICE

29709

DATE

3/20/23